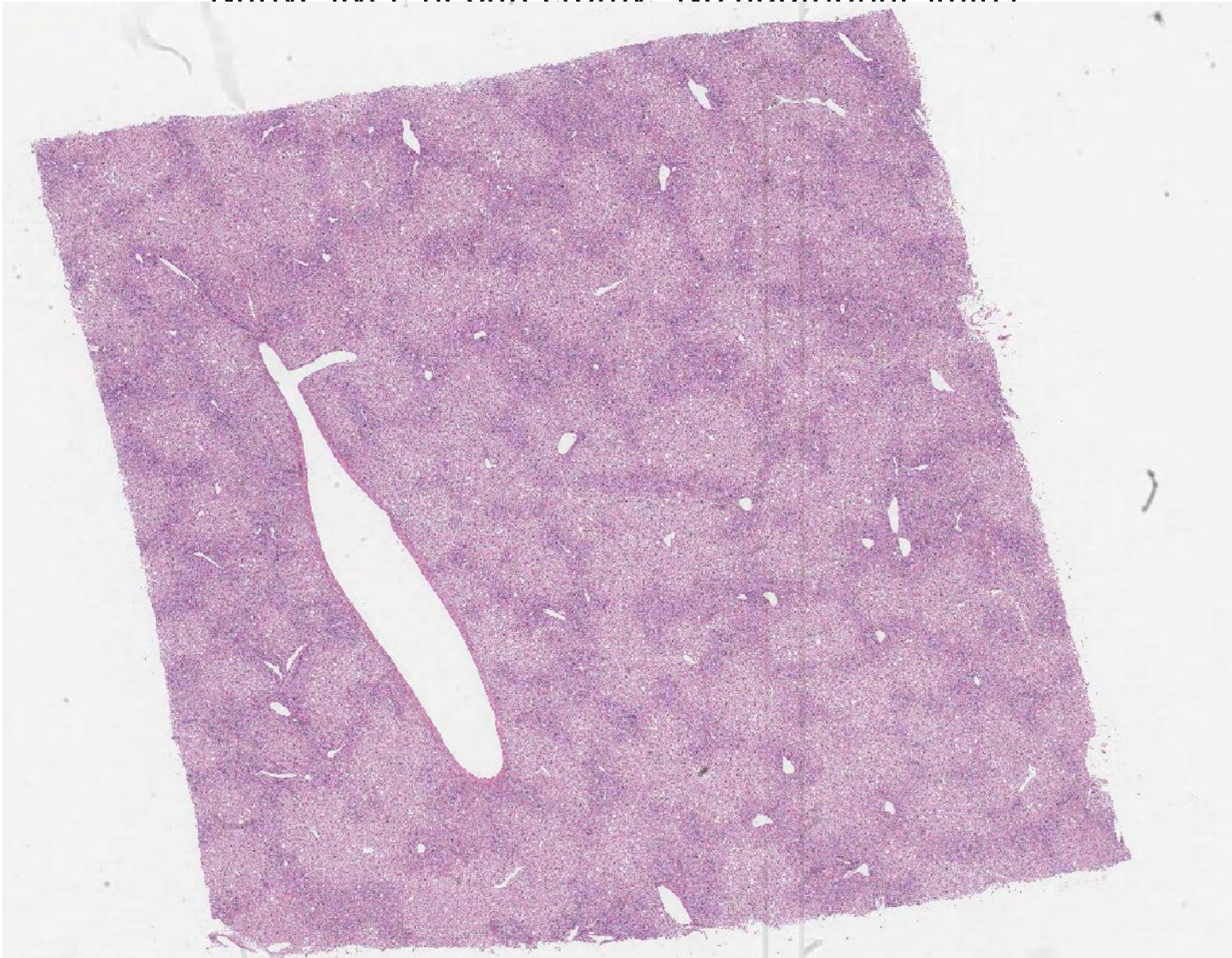


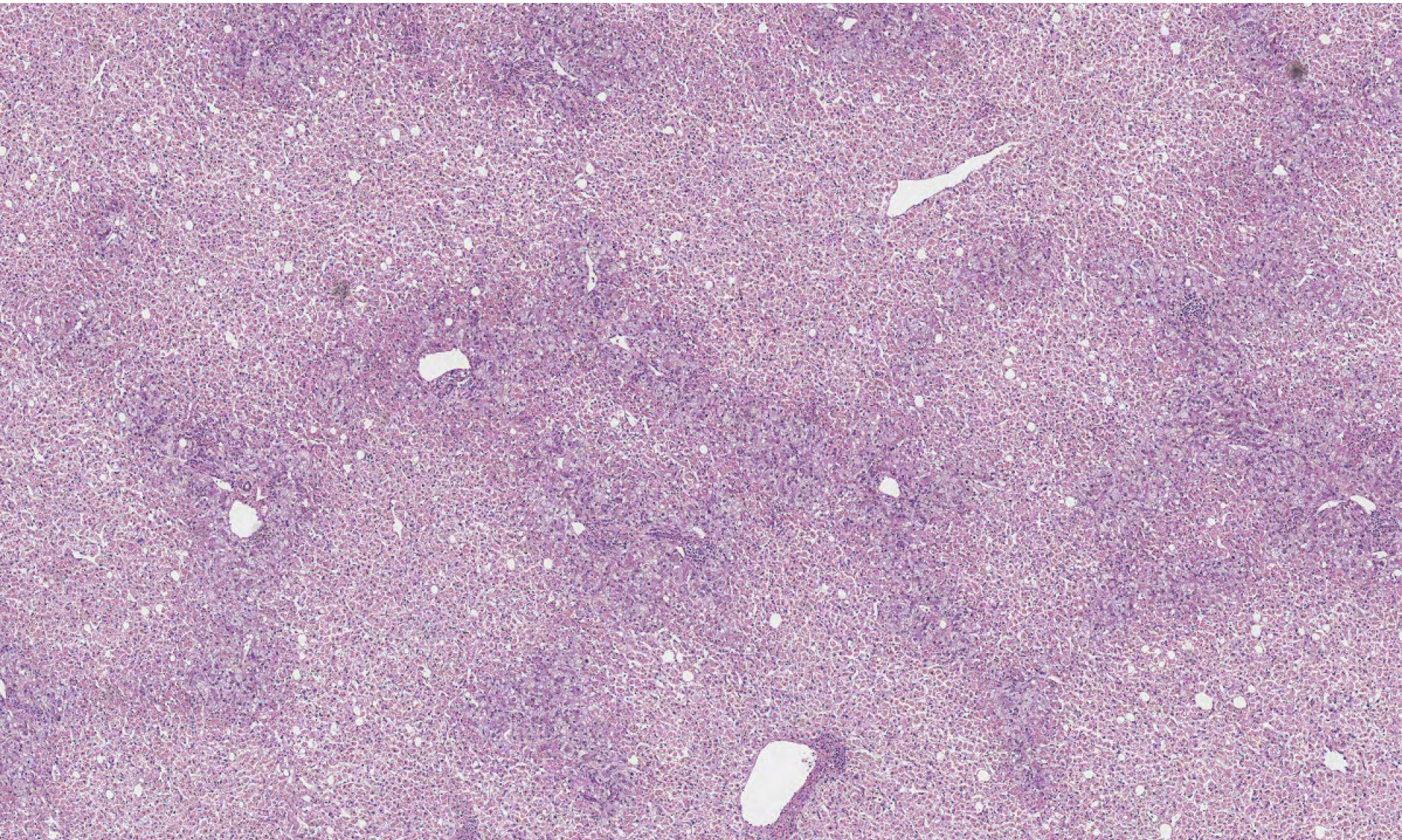
Case LS9 30 F

Paracetamol overdose

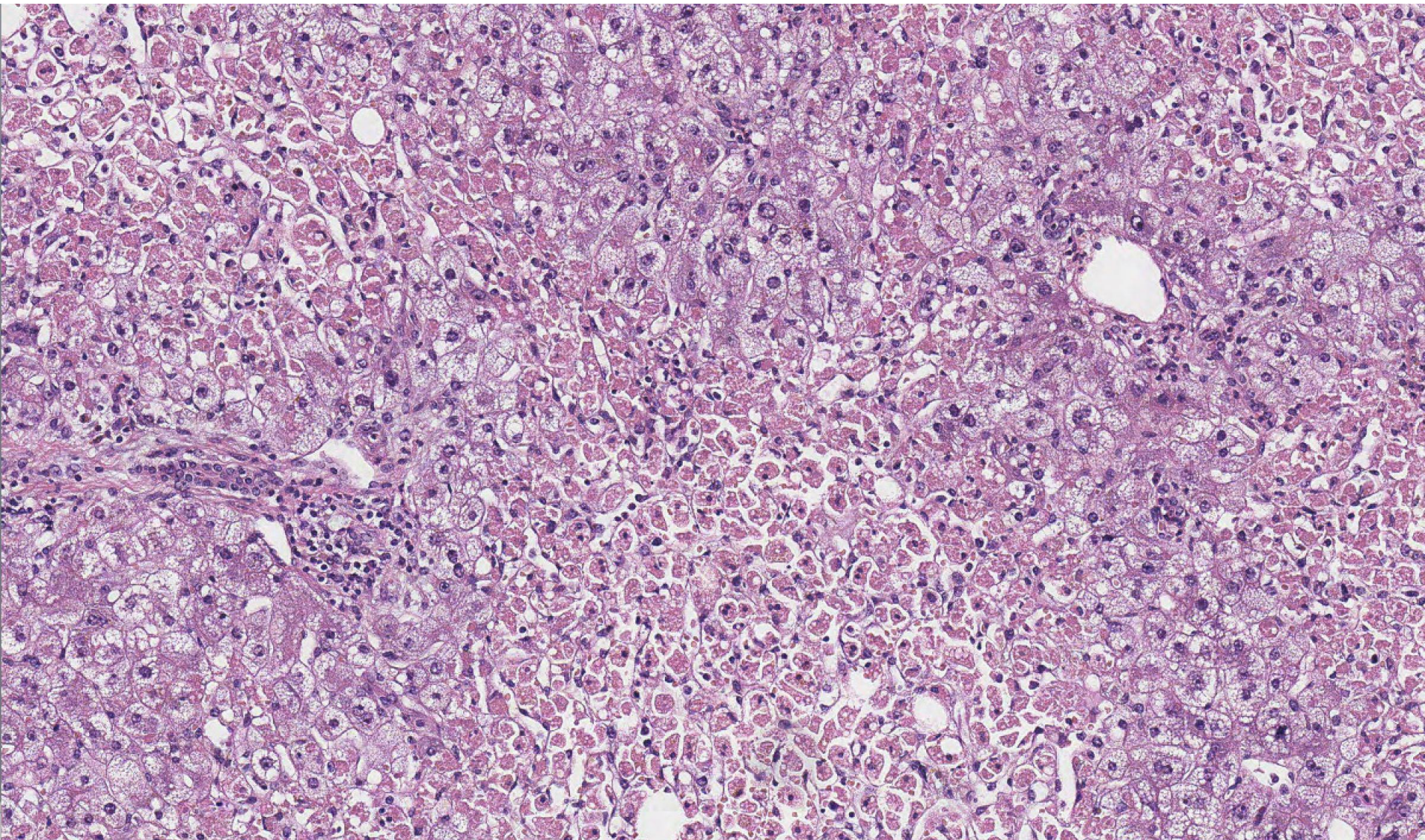
Native liver, hepatectomy. No additional stains



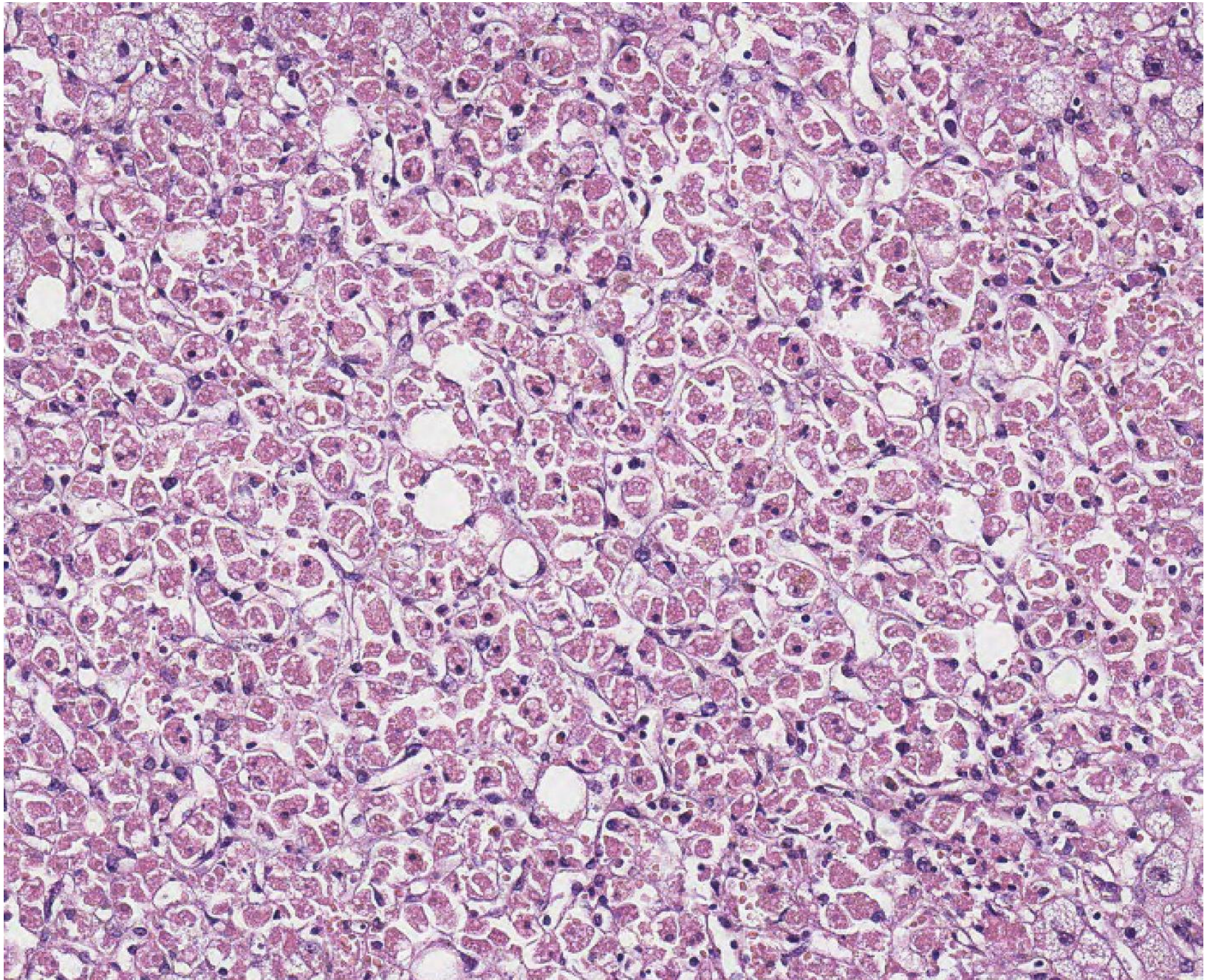
LS9



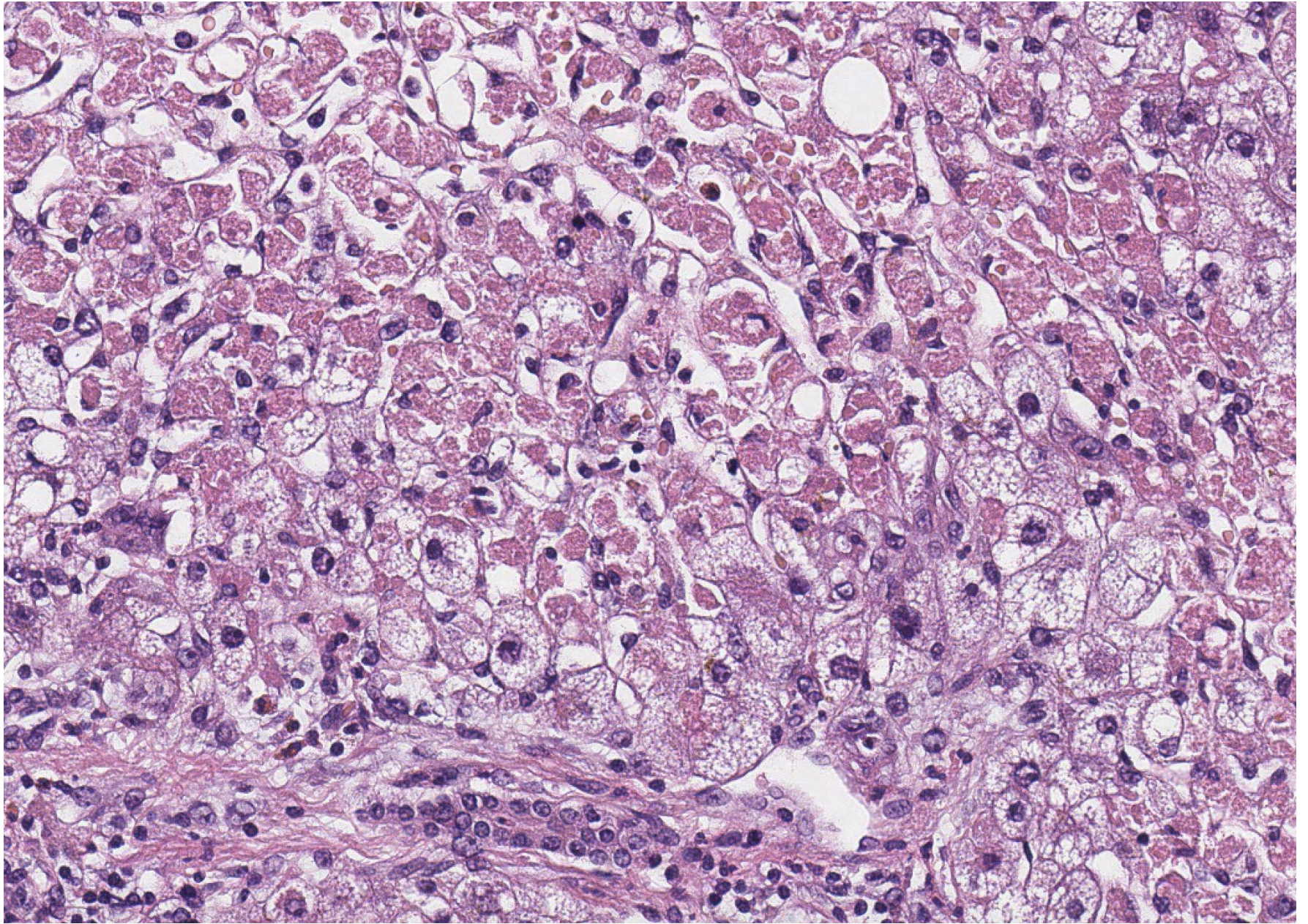
LS9



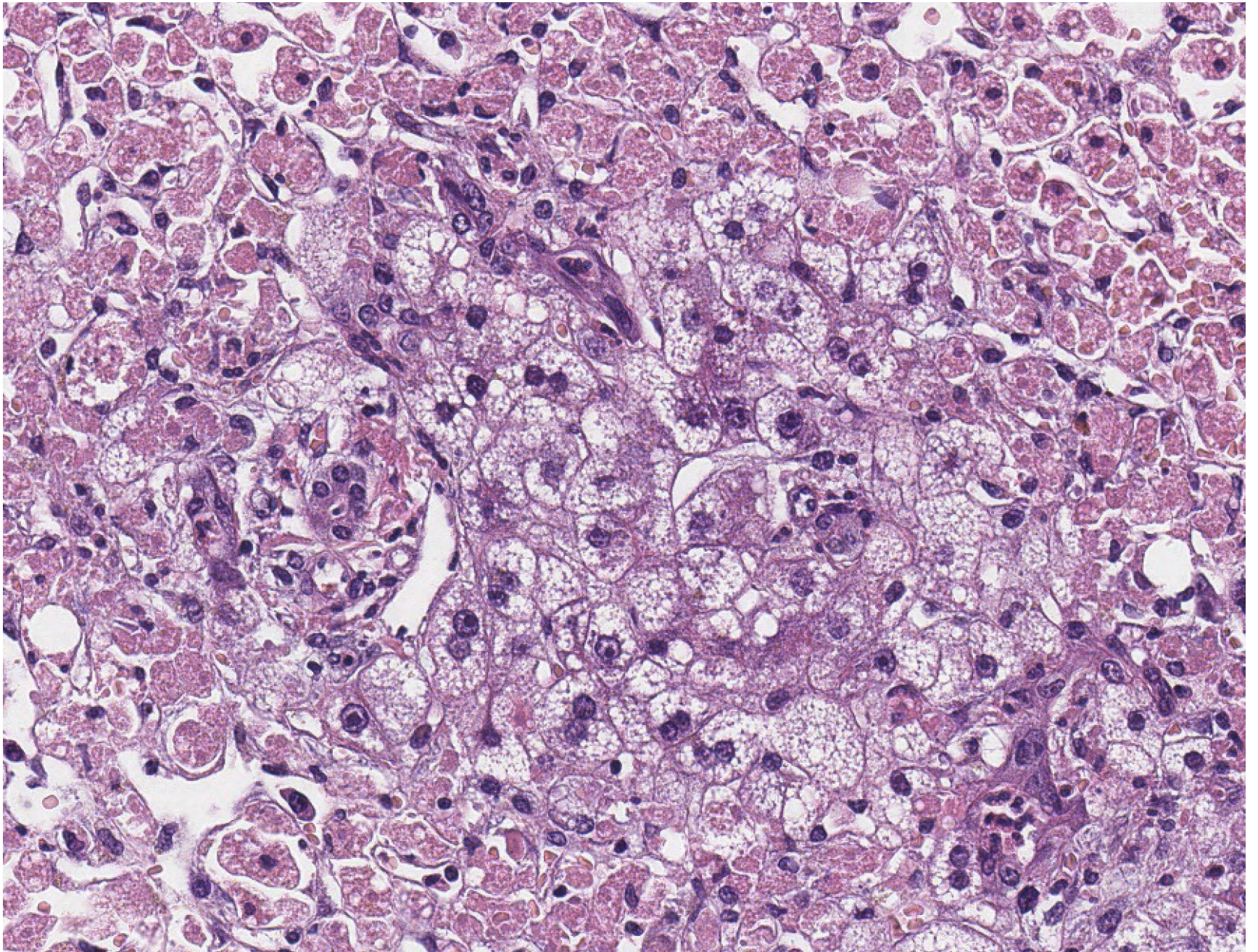
LS9



LS9



LS9



Case LS9 30 F

Paracetamol overdose

Native liver, hepatectomy. No additional stains

A	Ischaemic hepatopathy
B	Drug induced liver injury
C	Acute hepatitis with necrosis
D	Submassive necrosis
E	Zonal necrosis c/w paracetamol toxicity